VOLUME - XX
ISSUE - CXX
NOV/DEC 2023

# The Crux

BIMONTHLY FORUM FOR THE LABORATORIANS

CONTENTS



## Editorial

**Vitamin $B_{12}$ deficiency**, also known as **cobalamin deficiency**, is the medical condition in which the blood and tissue have a lower than normal level of vitamin $B_{12}$. Symptoms can vary from none to severe. Mild deficiency may have few or absent symptoms. In moderate deficiency, feeling tired, anemia, soreness of the tongue, mouth ulcers, breathlessness, feeling faint, rapid heartbeat, low blood pressure, pallor, hair loss, decreased ability to think and severe joint pain and the beginning of neurological symptoms, including abnormal sensations such as *pins and needles*, numbness and tinnitus may occur. Severe deficiency may include symptoms of reduced heart function as well as more severe neurological symptoms, including changes in reflexes, poor muscle function, memory problems, blurred vision, irritability, ataxia, decreased smell and taste, decreased level of consciousness, depression, anxiety, guilt and psychosis. If left untreated, some of these changes can become permanent. Temporary infertility reversible with treatment, may occur. In exclusively breastfed infants of vegetarian mothers who don't take B12 supplements as advised, undetected and untreated deficiency can lead to poor growth, poor development, and difficulties with movement. Treatment is by vitamin $B_{12}$ supplementation, either by mouth or by injection. Vitamin $B_{12}$ deficiency appears slowly and worsens over time, and can often be confused with other conditions. It may often go unrecognized, as the body becomes used to feeling unwell. This issue delves deep into **PERNICIOUS ANAEMIA** under **"DISEASE DIAGNOSIS"** segment. Pernicious anemia is a disease caused by an autoimmune response that produces antibodies that attack the parietal cells in the stomach lining, preventing them from creating intrinsic factor needed for the absorption of vitamin $B_{12}$.

The coenzyme A linked form of **methylmalonic acid**, methylmalonyl-CoA, is converted into succinyl-CoA by methylmalonyl-CoA mutase, in a reaction that requires vitamin $B_{12}$ as a cofactor. In this way, it enters the Krebs cycle, and is thus part of one of the anaplerotic reactions. **"INTERPRETATION"** interprets this very analyte for you.

**"TROUBLE SHOOTING"** highlights all aspects as related to Vitamin B12 assay.

So all in all this issue revolves around Vitamin B12.

The FUN PAGE titled **"BOUQUET"** lurks within the covers of this communiqué.

# DISEASE DIAGNOSIS

## PERNICIOUS ANEMIA

### Practice Essentials

The term "pernicious anemia" is an anachronism—it dates from the era when treatment had not yet been discovered, and the disease was fatal—but it remains in use to refer to an autoimmune disorder that affects the gastric mucosa's production of intrinsic factor (IF) leading to cobalamin (vitamin B12) deficiency and megaloblastic anemia. Impaired IF production in pernicious anemia occurs as a result of autoimmune destruction of parietal cells, which secrete IF, or the development of auto-antibodies targeted against IF itself. Other conditions that can result in impaired IF production include gastrectomy and a rare congenital autosomal recessive disorder that manifests with IF deficiency without gastric atrophy. Causes of megaloblastic anemia other than impaired IF production include folic acid deficiency, altered pH in the small intestine, and lack of absorption of vitamin B12 complexes in the terminal ileum. Thus, pernicious anemia must be differentiated from other disorders that interfere with the absorption and metabolism of vitamin B12 (see DDx and Workup). Clinical onset of pernicious anemia usually is insidious and vague. The classic triad of weakness, sore tongue, and paresthesias may be elicited but usually is not the chief symptom complex. Typically, medical attention is sought because of symptoms suggestive of cardiac, renal, genitourinary, gastrointestinal, infectious, mental, or neurologic disorders. Blood studies show anemia with macrocytic cellular indices. See Presentation.

Important goals in the management and care of patients with pernicious anemia include the following:

- Confirm that the patient has cobalamin deficiency.
- Initiate treatment with cobalamin. Use higher doses of cobalamin in patients with vitamin B12–associated CNS impairment.
- Provide concurrent treatment with folic acid and cobalamin in patients who demonstrate evidence for folic acid deficiency but also are being evaluated for pernicious anemia until the latter diagnosis has been ruled out, because although folic acid will restore blood counts, it will not prevent the development of subacute combined system degeneration in patients with pernicious anemia.
- Monitor response and effectiveness of cobalamin supplementation.
- Administer adequate quantities of cobalamin for the remainder of the patient's life.
- Evaluate the patient periodically to rule out gastric carcinoma.

### Pathophysiology

Cobalamin is an organometallic substance containing a corrin ring, a centrally located cobalt atom, and various axial ligands (see the image below).

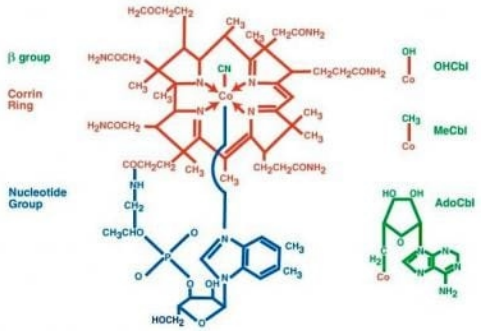


Pernicious anemia.

The structure of cyanocobalamin is depicted. The cyanide (Cn) is in green. Other forms of cobalamin (Cbl) include hydroxocobalamin (OHCbl), methylcobalamin (MeCbl), and deoxyadenosylcobalamin (AdoCbl). In these forms, the beta-group is substituted for Cn. The corrin ring with a central cobalt atom is shown in red and the benzimidazole unit in blue. The corrin ring has 4 pyrroles, which bind to the cobalt atom. The fifth substituent is a derivative of dimethylbenzimidazole. The sixth substituent can be Cn, CC3, hydroxycorticosteroid (OH), or deoxyadenosyl. The cobalt atom can be in a +1, +2, or +3 oxidation state. In hydroxocobalamin, it is in the +3 state. The cobalt atom is reduced in a nicotinamide adenine dinucleotide (NADH)–dependent reaction to yield the active coenzyme. It catalyzes 2 types of reactions, which involve either rearrangements (conversion of l methylmalonyl coenzyme A [CoA] to succinyl CoA) or methylation (synthesis of methionine). The basic structure known as vitamin B12 is solely synthesized by microorganisms, but most animals are capable of converting vitamin B12 into the two coenzyme forms, adenosylcobalamin and methylcobalamin. The former is required for conversion of *L*-methylmalonic acid to succinyl coenzyme A (CoA), and the latter acts as a methyltransferase for conversion of homocysteine to methionine. When either cobalamin or folate is deficient, thymidine synthase function is impaired. This leads to megaloblastic changes in all rapidly dividing cells because DNA synthesis is diminished. In erythroid precursors, macrocytosis and ineffective erythropoiesis occur. Severe neurologic impairment, usually subacute combined system degeneration, occurs in cobalamin deficiency. However, vitamin B12 deficiency can also present as peripheral neuropathy, psychosis, or leukoencephalopathy. Neurologic manifestations may occur independently of hematologic manifestations in pernicious anemia. The biochemical impairment in neurologic degeneration may differ from hematologic changes. Meat and milk are the main dietary sources of cobalamin. Because body stores of cobalamin usually exceed 1000 µg and the daily requirement is about 1 µg, strict adherence to a vegetarian diet for more than 5 years usually is required to produce findings of cobalamin deficiency. Dietary cobalamin is absorbed in a series of steps, which require proteolytic release from foodstuffs and binding to IF. Subsequently, recognition of the IF-cobalamin complex by specialized ileal receptors—cubilin receptors—must occur for transport into the portal circulation, where it is bound by transcobalamin II (TCII), which serves as the plasma transporter. The cobalamin-TCII complex binds to cell surfaces and is endocytosed. The transcobalamin is degraded within a lysozyme, and the cobalamin is released into the cytoplasm. An enzyme-mediated reduction of the cobalt occurs with either cytoplasmic methylation to form methylcobalamin or mitochondrial adenosylation to form adenosylcobalamin. Defects of these steps produce manifestations of cobalamin dysfunction. Most defects become manifest in infancy and early childhood and result in impaired development, mental retardation, and a macrocytic anemia. Certain defects cause methylmalonic aciduria and homocystinuria. See the image below.

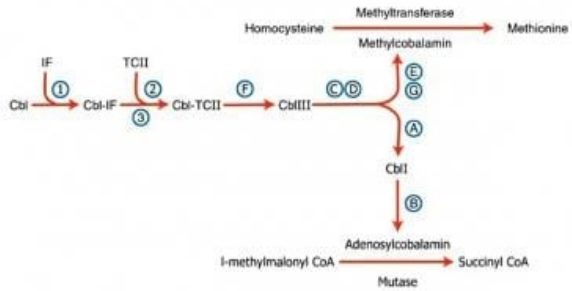

**Pernicious anemia.** Inherited disorders of cobalamin (Cbl) metabolism are depicted. The numbers and letters correspond to the sites at which abnormalities have been identified, as follows: (1) absence of intrinsic factor (IF); (2) abnormal Cbl intestinal adsorption; and (3) abnormal transcobalamin II (TC II), (a) mitochondrial Cbl reduction (Cbl A), (b) cobalamin adenosyl transferase (Cbl B), (c and d) cytosolic Cbl metabolism (Cbl C and D), (e and g) methyl transferase Cbl utilization (Cbl E and G), and (f) lysosomal Cbl efflux (Cbl F). Intrinsic factor is a gastric protein secreted by parietal cells that is necessary for vitamin B12 absorption. Pernicious anemia is an autoimmune disorder that leads to insufficient intrinsic factor levels either as a result of auto-antibody mediated destruction of parietal cells and/or the intrinsic factor protein itself. Parietal cell auto-antibodies target gastric H+/K+-ATPase. Other disorders that interfere with the absorption and metabolism of vitamin B12 can also result in cobalamin deficiency, with the development of a macrocytic anemia and neurologic complications. Antiparietal cell antibodies occur in 90% of patients with pernicious anemia but in only 5% of healthy adults. Similarly, binding and blocking antibodies to IF are found in most patients with pernicious anemia. A greater association than anticipated exists between pernicious anemia and other autoimmune diseases, including thyroid disorders, type 1 diabetes mellitus, ulcerative colitis, Addison disease, infertility, and acquired agammaglobulinemia. An association between pernicious anemia and *Helicobacter pylori* infections has been postulated but not clearly proven. Cobalamin deficiency may result from dietary insufficiency of vitamin B12; disorders of the stomach, small bowel, and pancreas; certain infections; and abnormalities of transport, metabolism, and utilization (see Etiology). Deficiency may be observed in strict vegetarians. Breastfed infants of vegetarian mothers also are affected. Severely affected infants of vegetarian mothers who do not have overt cobalamin deficiency have been reported.

Classic pernicious anemia produces cobalamin deficiency due to failure of the stomach to secrete IF (see the image below).

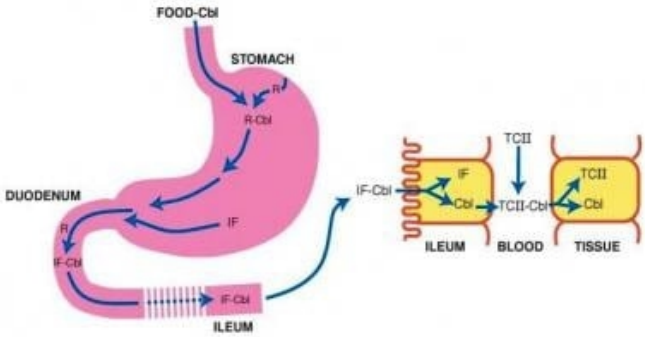


**Pernicious anemia.** Cobalamin (Cbl) is freed from meat in the acidic milieu of the stomach where it binds R factors in competition with intrinsic factor (IF). Cbl is freed from R factors in the duodenum by proteolytic digestion of the R factors by pancreatic enzymes. The IF-Cbl complex transits to the ileum where it is bound to ileal receptors. The IF-Cbl enters the ileal absorptive cell, and the Cbl is released and enters the plasma. In the plasma, the Cbl is bound to transcobalamin II (TC II), which delivers the complex to nonintestinal cells. In these cells, Cbl is freed from the transport protein. In adults, pernicious anemia is associated with severe gastric atrophy and achlorhydria, which are irreversible. Coexistent iron deficiency is common because achlorhydria prevents solubilization of dietary ferric iron from food. Autoimmune phenomena and thyroid disease frequently are observed. Patients with pernicious anemia have a 2- to 3-fold increased incidence of gastric carcinoma.

## Etiology

Cobalamin deficiency may result from the following:

- Inadequate dietary intake (ie, vegetarian diet)
- Atrophy or loss of gastric mucosa (eg, pernicious anemia, gastrectomy, ingestion of caustic material, hypochlorhydria, histamine 2 [H2] blockers)
- Functionally abnormal IF
- Inadequate proteolysis of dietary cobalamin
- Insufficient pancreatic protease (eg, chronic pancreatitis, Zollinger-Ellison syndrome [ZES])
- Bacterial overgrowth in intestine (eg, blind loop, diverticula) - bacteria compete with the body for cobalamin
- *Diphyllobothrium latum* (fish tapeworm) competes with the body for cobalamin
- Disorders of ileal mucosa (eg, resection, ileitis, sprue, lymphoma, amyloidosis, absent IF-cobalamin receptor, Imerslünd-Grasbeck syndrome, ZES, TCII deficiency, use of certain drugs)
- Disorders of plasma transport of cobalamin (eg, TCII deficiency, R binder deficiency)
- Dysfunctional uptake and use of cobalamin by cells (eg, defects in cellular deoxyadenosylcobalamin [AdoCbl] and methylcobalamin [MeCbl] synthesis)

Pernicious anemia is the most common cause of severe vitamin B12 deficiency worldwide and is due to autoimmune destruction of parietal cells and/or intrinsic factor. Children who develop cobalamin deficiency usually have a hereditary disorder, and the etiology of their cobalamin deficiency is different from the etiology observed in classic pernicious anemia. Congenital pernicious anemia is a hereditary disorder in which an absence of IF occurs without gastric atrophy due to genetic abnormalities that result in failure to secrete IF or production of defective IF. Other gastric conditions that cause cobalamin deficiency are gastrectomy, gastric stapling, and bypass procedures for obesity and extensive infiltrative disease of the gastric mucosa. Usually, these conditions are associated with a decreased ability to mobilize cobalamin from food rather than a malabsorption of cobalamin; thus, such patients may exhibit a normal finding on a Schilling test (stage I). Pancreatic insufficiency can produce cobalamin deficiency. Nonspecific R binders chelate cobalamin in the stomach, making it unavailable for binding to IF. Pancreatic proteases degrade the R binders and release the cobalamin so that it can bind IF. The cobalamin-IF complex is formed so that it can bind ileal receptors that enable uptake by absorptive cells. Thus, patients with chronic pancreatitis may have impaired absorption of cobalamin. Cobalamin deficiency is also reported in ZES. The mechanism is believed to be due to the acidic pH of the distal small intestine, which hinders the cobalamin-IF complex from effectively binding to the ileal receptors. Disorders of the ileum cause cobalamin deficiency as a consequence of the loss of the ileal receptors for the cobalamin-IF complex. Thus, surgical loss of the ileum and diseases such as tropical sprue, regional enteritis, ulcerative colitis, and ileal lymphoma interfere with cobalamin absorption. Genetic defects of the ileal receptors for IF (ie, Imerslünd-Grasbeck syndrome) and hereditary transcobalamin I (TCI) deficiency produce cobalamin deficiency from birth and are usually discovered early in life. Many drugs impair cobalamin uptake in the ileum but are rarely a cause of symptomatic vitamin B12 deficiency, because they are not taken for long enough to deplete body stores of cobalamin. Such agents include nitrous oxide, cholestyramine, *para* -aminosalicylic acid, neomycin, metformin, phenformin, and colchicine. The clinical manifestations of inherited defects of cobalamin transport and metabolism are usually observed in

infancy and childhood. Thus, they are discussed only briefly in this article. Three hereditary disorders affect absorption and transport of cobalamin, and another seven alter cellular use and coenzyme production. The three disorders of absorption and transport are TCII deficiency, IF deficiency, and IF receptor deficiency. These defects produce developmental delay and a megaloblastic anemia, which can be alleviated with pharmacologic doses of cobalamin. Serum cobalamin values are decreased in the two IF abnormalities but may be within the reference range in TCII deficiency. The seven abnormalities of cellular use, commonly denoted by letters A through G, can be detected by the presence or absence of methylmalonic aciduria and homocystinuria. The presence of only methylmalonic aciduria indicates a block in conversion of methylmalonic CoA to succinyl CoA and results in either a genetic deficit in the methylmalonyl CoA mutase that catalyzes the reaction or a defect in synthesis of its CoA cobalamin (cobalamin A and cobalamin B deficiency). The presence of only homocystinuria results either from poor binding of cobalamin to methionine synthase (cobalamin E deficiency) or from producing methylcobalamin from cobalamin and S adenosylmethionine (cobalamin G deficiency). This results in a reduction in methionine synthesis, with pronounced homocystinemia and homocystinuria. Methylmalonic aciduria and homocystinuria occur when the metabolic defect impairs reduction of cobalamin III to cobalamin II (cobalamin C, cobalamin D, and cobalamin F deficiency). This reaction is essential for formation of both methylmalonic acid and homocystinuria. Early detection of these rare disorders is important because most patients respond favorably to large doses of cobalamin. However, some of these disorders are less responsive than others, and delayed diagnosis and treatment are less efficacious. Abnormalities in the intestinal lumen may produce cobalamin deficiency. Individuals with blind intestinal loops, stricture, and large diverticula may develop bacterial overgrowth, which sequesters dietary cobalamin for their metabolic needs. Tapeworm infestation with *Diphyllobothrium latum* occurs from eating poorly cooked lake fish that are infected and causes cobalamin deficiency because the parasites have a high requirement for cobalamin.

## Epidemiology

Adult pernicious anemia usually occurs in people aged 40-70 years. One study found 1.9% of patients older than 60 had undiagnosed pernicious anemia. Congenital pernicious anemia usually manifests in children younger than 2 years. Whereas the disease originally was believed to be restricted primarily to whites of Scandinavian and Celtic origin, subsequent evidence shows that it occurs in all races. In general, the prevalence of pernicious anemia is probably underestimated, due to the complexity of the diagnosis. A female predominance has been reported in England, Scandinavia, and among persons of African descent (1.5:1). However, data in the United States show an equal sex distribution. Pernicious anemia likely has a genetic predisposition. The disease is diagnosed more commonly in family members of patients diagnosed with pernicious anemia and is associated with human leukocyte antigen (HLA) types A2, A3, and B7 and blood group type A. Approximately 20% of relatives of patients with pernicious anemia are diagnosed with the same condition. Patients with pernicious anemia have an increased incidence of autoimmune disorders and thyroid disease, suggesting that the disease has an immunologic component. For example, pernicious anemia may occur together with autoimmune thyroid disease, type 1A diabetes mellitus, alopecia, vitiligo, and chronic atrophic gastritis in type III polyglandular autoimmune (PGA) syndrome—one of a rare group of disorders also known as autoimmune polyendocrine syndromes (APS) and polyglandular failure syndromes.

## Prognosis

The term pernicious anemia dates from the mid-1800s and reflects the disease's high fatality rate at the time, when its etiology had not yet been discovered. The megaloblastic appearance of cells led many to speculate that it was a neoplastic disease. In the 1920s, however, the response of patients to liver therapy suggested that a nutritional deficiency was responsible for the disorder. This became obvious in clinical trials once vitamin B12 was isolated. Currently, early recognition and treatment of pernicious anemia provide a normal, and usually uncomplicated, lifespan. Delayed treatment permits progression of the anemia and neurologic complications. If patients are not treated early in the disease, neurologic complications can become permanent. Severe anemia can cause congestive heart failure or precipitate coronary insufficiency. Although vitamin B12 therapy resolves the anemia, it does not cure the atrophic gastritis, which can progress to gastric cancer. The incidence of gastric adenocarcinoma is 2- to 3-fold greater in patients with pernicious anemia than in the general population of the same age. Presently, periodic gastroscopy and/or barium roentgenographic studies are not advocated in patients with treated pernicious anemia who are asymptomatic, because such screening has not been demonstrated to prolong lifespan. A population-based, case-control study using the Surveillance, Epidemiology, and End Results (SEER)–Medicare database found that elderly persons with pernicious anemia were not only at significantly increased risk for noncardia gastric adenocarcinoma (odds ratio [OR] 2.18) and gastric carcinoid tumors (OR, 11.43), they were also at increased risk for the following :

- Tonsillar cancer (OR, 2.00)
- Hypopharyngeal cancer (OR, 1.92)
- Esophageal squamous cell carcinoma (OR, 2.12)
- Small intestinal cancer (OR, 1.63)
- Liver cancer (OR, 1.49)
- Myeloma (OR, 1.55)
- Acute myeloid leukemia (OR, 1.68)
- Myelodysplastic syndrome (OR, 2.87)

In a longitudinal study of 199 intrinsic factor antibody (IFA)–positive and 168 IFA-negative Chinese patients, Chan et al found that despite a good hematologic response to therapy, both groups had an unsatisfactory neurologic response, and newly diagnosed hypothyroidism was found during follow-up. In addition, newly diagnosed cancers were also found (24 in IFA-positive patients, seven in IFA-negative patients), of which 20% were gastric cancer. For the IFA-positive patients with a cancer, mean survival was 64 months; for those without a cancer, it was 129 months. Mortality was 31% in this group, in which cancer-related deaths represented 37% of the total. For the IFA-negative patients with a cancer, mean survival was 36 months. For those without a cancer, it was 126 months. Mortality was 21% in this group, in which cancer-related deaths represented 14% of the total.

## Patient Education

Lifelong compliance in obtaining adequate vitamin B12 by injection (or possibly orally) is necessary to avoid relapse of pernicious anemia.

For patient education resources, see Pernicious Anemia (Vitamin B-12 Deficiency) and Vitamin B12.

## Pernicious Anemia Clinical Presentation

### History

The onset of pernicious anemia usually is insidious and vague. The classic triad of weakness, sore tongue, and paresthesias may be elicited

but usually is not the chief symptom complex. Typically, medical attention is sought because of symptoms suggestive of cardiac, renal, genitourinary, gastrointestinal, infectious, mental, or neurologic disorders, and the patient is found to be anemic with macrocytic cellular indices.

General symptoms

Weight loss of 10-15 lb occurs in about 50% of patients and probably is due to anorexia, which is observed in most patients. Low-grade fever occurs in one third of newly diagnosed patients and promptly disappears with treatment.

Cardiac symptoms

Individuals with pernicious anemia often tolerate the anemia well, and many are ambulatory with hematocrit levels in the mid-teens. However, the cardiac output is usually increased when hematocrit levels fall below 20%, with associated accerations in heart rate. Congestive heart failure and coronary insufficiency can occur, most particularly in patients with preexisting heart disease.

Gastrointestinal symptoms

Approximately 50% of patients with pernicious anemia develop atrophic glossitis, presenting with a smooth tongue that may be painful and beefy red, with loss of papillae that is usually most marked along the edges of the tongue. These patients report burning or soreness, most particularly on the anterior third of the tongue, associated with changes in taste and loss of appetite. Patients may report either constipation or having several semisolid bowel movements daily. These symptoms have been attributed to megaloblastic changes of the cells of the intestinal mucosa.

Nonspecific gastrointestinal (GI) symptoms are not unusual and include anorexia, nausea, vomiting, heartburn, pyrosis, flatulence, and a sense of fullness. Rarely, patients present with severe abdominal pain associated with abdominal rigidity; this has been attributed to spinal cord pathology. Venkatesh and colleagues report the case of a patient who presented with epigastric pain, diarrhea, and vomiting and was found to have thrombosis of the portal, superior mesenteric, and splenic veins due to hyperhomocysteinemia secondary to pernicious anemia.

Neurologic symptoms

The most common neurologic symptoms in vitamin B12 deficiency include paresthesias, weakness, clumsiness, and an unsteady gait. The last two symptoms are exacerbated in dark environments due to the loss of visual cues that patients often rely on, in concert with the loss of proprioception. These neurologic symptoms are due to myelin degeneration and loss of nerve fibers in the dorsal and lateral columns of the spinal cord and cerebral cortex (subacute combined degeneration). Neurologic symptoms and findings may be present in the absence of anemia. This is more common in patients taking folic acid or on a high-folate diet. Older patients may present with symptoms suggesting senile dementia or Alzheimer disease; memory loss, irritability, and personality changes are commonplace. So-called megaloblastic madness—delusions, hallucinations, outbursts, and paranoid schizophrenic ideation—is less common. Identifying the cause is important because significant reversal of these symptoms and findings can occur with vitamin B12 administration. While neurologic symptoms usually occur in the elderly, they can rarely occur in the young. Kocaoglu et al reported a case of vitamin B12 deficiency and cerebral atrophy in a 12-month-old infant whose development had slowed since 6 months of age; the infant was exclusively breastfed and his mother was a long-time vegetarian. Neurologic recovery began within days after the infant received an intramuscular cobalamin injection.

Genitourinary symptoms

Urinary retention and impaired micturition may occur because of spinal cord damage. This can predispose patients to urinary tract infections.

Symptoms of thrombotic complications

A study of four patients revealed that pernicious anemia can lead to hyperhomocysteinemia that is significant enough to lead to venous thrombosis, even in the absence of any other risk factors for thromboembolism.

## Physical Examination

The finding of severe anemia in an adult patient whose constitutional symptoms are relatively mild and in whom weight loss is not a major feature should arouse suspicion of pernicious anemia. Typically, patients with pernicious anemia are described as having a stereotypic appearance: they have a lemon-yellow waxy pallor with premature whitening of the hair, and they appear flabby, with a bulky frame that is generally incongruent with the severe anemia and weakness. It should be remembered, however, that whereas this characterization is useful in patients of northern European descent, it is less helpful in patients of other ethnic groups (who, as noted, are more commonly affected than was once believed).

The following signs may be noted:

- Low-grade fever and mild icterus are commonplace but are usually mild and easily missed.
- A beefy, red, smooth tongue may be observed.
- In patients with dark complexions, blotchy skin pigmentation may be observed.
- Tachycardia often is present and may be accompanied by flow murmurs.
- Abnormal mentation and deterioration of vision and hearing may be observed.
- With severe anemia, dyspnea, tachypnea, and evidence of congestive heart failure may be present.
- Retinal hemorrhages and exudates may accompany severe anemia.
- The liver may be enlarged in association with congestive heart failure.
- A splenic tip is palpable in about 20% of patients.

Neurologic assessment

A careful neurologic assessment is important. All megaloblastic disorders can give rise to hematologic and epithelial manifestations, but only cobalamin deficiency causes neurologic deficits. Neurologic findings may occur in the absence of anemia and epithelial manifestations of pernicious anemia, making it more difficult to identify the etiology. If left untreated, they can become irreversible. Suspect pernicious anemia in all patients with recent loss of mental capacities. Somnolence, dementia, psychotic depression, and frank psychosis may be observed, which can be reversed or improved by treatment with cobalamin. Perversion of taste and smell and visual disturbances, which can progress to optic atrophy, can likewise result from central nervous system (CNS) cobalamin deficiency. A history of either paresthesias in the fingers and toes or difficulty with gait and balance should prompt a careful neurologic examination. Loss of position sense in the second toe and loss of vibratory sense for a 256-Hz tuning fork, but not for a 128-Hz fork, are the earliest signs of posterolateral column disease. If untreated, this can progress to spastic ataxia from demyelinization of the dorsal and lateral columns of the spinal cord.

## Pernicious Anemia Differential Diagnoses

## Diagnostic Considerations

By definition, pernicious anemia refers specifically to vitamin B12 deficiency resulting from a lack of production of intrinsic factor (IF) in the stomach. However, vitamin B12 absorption is a complex process, and

other causes of vitamin B12 deficiency exist. Pernicious anemia must be differentiated from other disorders that interfere with the absorption and metabolism of vitamin B12 and produce cobalamin deficiency, with the development of a macrocytic anemia and neurologic complications. Go to Anemia, Iron Deficiency Anemia, and Chronic Anemia for complete information on these topics. Thiamine-responsive megaloblastic anemia syndrome (TRMA) is an autosomal recessive disorder characterized by megaloblastic anemia, progressive sensorineural hearing loss, and diabetes mellitus. Onset of megaloblastic anemia occurs between infancy and adolescence. Vitamin B12 and folic acid levels are normal. On bone marrow examination, affected individuals have megaloblastic changes with erythroblasts often containing iron-filled mitochondria (ringed sideroblasts). Molecular genetic testing will show biallelic pathogenic variants in *SLC19A2*. Uncommonly, variable ocular anomalies may be present in TRMA. One case report describes symmetric bull's eye maculopathy and other ocular findings consistent with cone-rod degeneration. The anemia in TRMA is corrected with pharmacologic doses (50-100 mg/day) of thiamine (vitamin B1). However, the red cells remain macrocytic.

Other conditions to be considered include the following:

- Cestode infection
- Neurologic disorders
- Senility

Pernicious anemia may rarely be associated with liver disease (eg, primary biliary cholangitis, autoimmune hepatitis, interferon-treated hepatitis C). Yan et al report two cases of pernicious anemia in patients with cryptogenic cirrhosis, in both of whom the neuropsychiatric symptoms of pernicious anemia were initially attributed to hepatic encephalopathy.

### Differential Diagnoses

- Achlorhydria
- Alcoholic Fatty Liver
- Alcoholic Hepatitis
- Anemia
- Atrophic Gastritis
- Bone Marrow Failure
- Celiac Disease (Sprue)
- Cirrhosis
- Folate Deficiency
- Gastric Cancer
- Hemolytic Anemia
- Hyperthyroidism and Thyrotoxicosis
- Hypothyroidism
- Immune Thrombocytopenia (ITP)
- Iron Deficiency Anemia
- Macrocytosis
- Malabsorption
- Megaloblastic Anemia
- Myeloproliferative Disease
- Tropical Sprue
- Unconjugated Hyperbilirubinemia
- Zollinger-Ellison Syndrome

## Pernicious Anemia Workup

### Approach Considerations

The workup for pernicious anemia may include the following:

- Complete blood cell count (CBC)
- Peripheral blood smear
- Indirect bilirubin and lactate dehydrogenase assays
- Evaluation of gastric secretions
- Serum cobalamin, folic acid, methylmalonic acid, and homocysteine assays
- Schilling test (no longer available in most medical centers)
- A clinical trial of vitamin B12
- Bone marrow aspiration and biopsy

#### CBC and Peripheral Blood Smear

The mean corpuscular volume (MCV) and mean cell hemoglobin (MCH) are increased, with a mean corpuscular hemoglobin concentration (MCHC) within the reference range. The peripheral blood usually shows a macrocytic anemia with a mild leukopenia and thrombocytopenia (see the image below). The leukopenia and thrombocytopenia usually parallel the severity of the anemia.

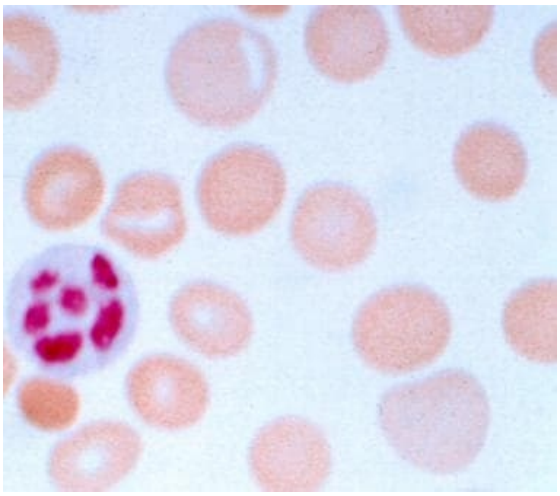

Peripheral smear of blood from a patient with pernicious anemia. Macrocytes are observed, and some of the red blood cells show ovalocytosis. A 6-lobed polymorphonuclear leucocyte is present.

The peripheral smear shows oval macrocytes, hypersegmented granulocytes, and anisopoikilocytosis. In severe anemia, red blood cell inclusions may include Howell-Jolly bodies, Cabot rings, and punctate basophilia. The macrocytosis can be obscured by the coexistence of iron deficiency, thalassemia minor, or inflammatory disease.

#### Indirect Bilirubin and Serum Lactate Dehydrogenase

The indirect bilirubin level may be elevated because pernicious anemia is a hemolytic disorder associated with increased turnover of bilirubin. The serum lactate dehydrogenase (LDH) concentration usually is markedly increased. Hemolysis is intramedullary. Increased values for other red blood cells, enzymes, and serum iron saturation also are observed. The serum potassium, cholesterol, and skeletal alkaline phosphatase often are decreased.

#### Evaluation of Gastric Secretions

Total gastric secretions are decreased to about 10% of the reference range. Most patients with pernicious anemia are achlorhydric, even with histamine stimulation. Intrinsic factor (IF) is either absent or markedly decreased.

#### Serum Cobalamin

Serum cobalamin reference ranges may vary slightly among different laboratories, but are generally from 200–900 pg/mL. Values of 180-250 pg/mL are considered bordeline, while less than 150 pg/mL is considered diagnostic of vitamin B12 deficiency. The serum cobalamin level is usually low in patients with pernicious anemia. However, up to a third of patients can present with normal vitamin B12 levels and

normocytic anemia, which often delays diagnosis. Certain patients with other forms of cobalamin deficiency, such as some inborn forms of cobalamin deficiency, transcobalamin II (TCII) deficiency, and cobalamin deficiency due to nitrous oxide, can also present with normal serum cobalamin levels. Conversely, serum cobalamin levels may be low in patients with no clinical or identifiable metabolic abnormality. Causes of falsely low serum cobalamin levels inclue the following:

- Pregnancy
- Oral contraceptives and hormone replacement therapy
- Multiple myeloma
- Transcobalamin I (TCI) deficiency
- Severe folic acid deficiency
- Ascorbic acid in high doses

Serum cobalamin levels can be in the low reference range in patients with clinical vitamin B12 deficiency. In these cases, elevated levels of methylmalonic acid and total homocysteine can confirm the diagnosis. Screening of older individuals has shown that 10-20% have low serum cobalamin levels, and half of these patients have increased levels of homocysteine and methylmalonic acid, indicating a tissue cobalamin deficiency.

### Serum Folic Acid, Methylmalonic Acid, and Homocysteine

A serum folic acid assay is useful for ruling out folic acid deficiency. The reference range is 2.5-20 ng/mL. Blood should be drawn before patients have a single hospital meal since food can restore serum folic acid levels to normal. Red blood cell folic acid level is not influenced by food. (For more information, see Megaloblastic Anemia and Folic Acid Deficiency).

A significantly decreased serum cobalamin level along with a typical clinical presentation, a characteristic peripheral smear, and an increased indirect bilirubin and LDH level is sufficient evidence for the diagnosis of a megaloblastic anemia. Serum methylmalonic acid and homocysteine tests are important confirmatory tests but are not first-line tests. Elevated serum methylmalonic acid and homocysteine levels are found in patients with pernicious anemia. They probably are the most reliable test for cobalamin deficiency in patients who do not have a congenital metabolism disorder (see the table below). In the absence of an inborn error of methylmalonic acid metabolism, methylmalonic aciduria is a sign of cobalamin deficiency.

**Table 1.** Serum Methylmalonic Acid and Homocysteine Values Used in Differentiating Between Cobalamin and Folic Acid Deficiency (Open Table in a new window)

| Patient Condition | Methylmalonic Acid | Homocysteine |
|---|---|---|
| Healthy | Normal | Normal |
| Vitamin B12 deficiency | Elevated | Elevated |
| Folate deficiency | Normal | Elevated |

### Intrinsic Factor Antibodies

Demonstration of circulating intrinsic factor autoantibodies is almost diagnostic of type A (autoimmune) gastritis and pernicious anemia. Intrinsic factor (IF) antibodies are specific for this disorder and can be used to confirm the diagnosis. There are two types of IF antibodies. Type I IF antibodies block binding of vitamin B12 to intrinsic factor and are found in 70% to 90% of patients with pernicious anemia. Type II IF antibodies prevent attachment of the vitamin B12–IF complex to ileal receptors and are present in approximately 35% to 50% of patients with pernicious anemia; they rarely occur in the absence of type I IF antibodies. Both type I and type II antibodies are detected more often in gastric juice than in the serum. In one case report, the presence of IF antibodies was used to diagnose cobalamin deficiency in a patient with severe leukoencephalopathy. Interestingly, serum vitamin B12, homocysteine, and methylmalonic acid levels were normal. The patient responded to intensive cobalamin therapy. Parietal cell antibodies occurs in 90% of patients with pernicious anemia. However, these antibodies are not specific for pernicious anemia.

### Schilling Test

The Schilling test measures cobalamin absorption by assessing increased urine radioactivity after an oral dose of radioactive cobalamin. The test is useful in demonstrating that the anemia is caused by an absence of IF and is not secondary to other causes of cobalamin deficiency (see the table below). It is also useful for identifying patients with classic pernicious anemia, even after they have been treated with vitamin B12. However, the Schilling test is no longer available in most medical centers.

**Table 2.** Schilling test results (Open Table in a new window)

| Patient Condition | Stage I No Intrinsic Factor | Stage II Intrinsic Factor | Stage III Antibiotic | Stage IV Pancreatic Extract |
|---|---|---|---|---|
| Healthy | Normal | … | … | … |
| Pernicious anemia | Low | Normal | … | … |
| Bacterial overgrowth | Low | Low | Normal | … |
| Pancreatic insufficiency | Low | Low | Low | Normal |
| Defect in ileum | Low | Low | Low | Low |

The test is performed by administering 0.5-2.0 mCi of radioactive cyanocobalamin in a glass of water to patients who have fasted. Two hours later, the patient is injected with 1 mg of unlabeled vitamin B12 to saturate circulating transcobalamins. A 24-hour urine sample is collected, and the radioactivity in the specimen is measured and compared to a standard. Specimens with less than 7% excretion represent abnormal findings and indicate that poor absorption of the oral test dose occurred. If abnormal low values are obtained, a stage II Schilling test is performed. In this test, 60 mg of active hog IF is administered with the oral test dose to determine if this enhances the absorption of vitamin B12. If poor absorption of vitamin B12 is normalized, the patient presumably has classic pernicious anemia. If poor absorption is observed in a stage II test, other causes of vitamin B12 malabsorption must be sought. Performance of a stage I Schilling test after 5 days of tetracycline therapy is used to exclude a blind loop as the etiology for cobalamin deficiency (stage III). Similarly, if administration of trypsin or pancreatic enzyme with the radiolabeled test dose corrects the absorption of vitamin B12, pancreatic disease (stage IV) should be suspected. False-positive Schilling test results are observed in patients with incomplete 24-hour urine collections or renal insufficiency. False-positive results are also observed when inactive IF is used. Finally, false-positive results may occur because of neutralization of the IF in the stage II test by any IF antibodies in the stomach and severe ileal megaloblastosis. Occasionally, cobalamin deficiency and a normal stage I Schilling test result are observed. Patients with these findings can absorb vitamin B12 in the fasting state, but not when it is presented with food. Adding the radiolabeled vitamin B12 to egg white and testing the absorption usually reveals this cause of cobalamin deficiency.

### Clinical Trial of Vitamin B12

Intramuscular (IM) administration of 1000 µg of vitamin B12 can be used as a clinical trial for suspected cobalamin deficiency. Subjectively,

patients who are cobalamin deficient usually begin to experience a marked sense of well-being within 24 hours after administration. Objectively, administration of cobalamin produces a marked reticulocytosis, which reaches its maximal level 5-7 days after the injection; correction of the anemia occurs in about 3 weeks (see the image below).

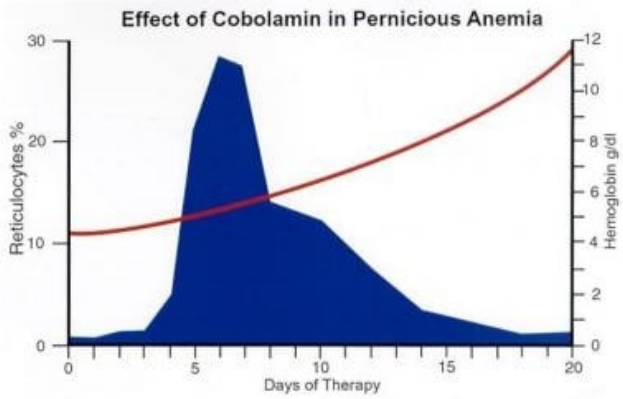


Response to therapy with cobalamin (Cbl) in a previously untreated patient with pernicious anemia. A reticulocytosis occurs within 5 days after an injection of 1000 mcg of Cbl and lasts for about 2 weeks. The hemoglobin (Hgb) concentration increases at a slower rate because many of the reticulocytes are abnormal and do not survive as mature erythrocytes. After 1 or 2 weeks, the Hgb concentration increases about 1 g/dL per week.

### Bone Marrow Aspiration and Biopsy

Bone marrow aspiration and biopsy can provide complementary information, with the aspirate revealing the numerical and cytological features of marrow cells, while the biopsy shows the spatial relationships between cells and the overall marrow structure. The bone marrow biopsy and aspirate specimens usually are hypercellular and show trilineage differentiation. Erythroid precursors are large and often oval (see the image below).

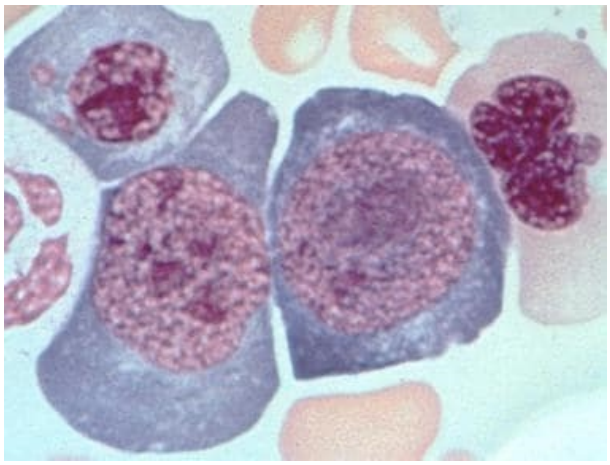

Bone marrow aspirate from a patient with untreated pernicious anemia. Megaloblastic maturation of erythroid precursors is shown. Two megaloblasts occupy the center of the slide with a megaloblastic normoblast above.

The nucleus is large and contains coarse motley chromatin clumps, providing a checkerboard appearance. Nucleoli are visible in the more immature erythroid precursors. An imbalance in the rate of maturation of the nucleus relative to the cytoplasm exists, leading to disassociation between the maturity of the nucleus and the hemoglobinization of the orthochromic megaloblastic normoblasts. Giant metamyelocytes and bands are present, and the mature neutrophils and eosinophils are hypersegmented. Imbalanced growth of megakaryocytes is evidenced by hyperdiploidy of the nucleus and the presence of giant platelets in the smear. Lymphocytes and plasma cells are spared from the cellular gigantism and cytoplasmic asynchrony observed in other cell lineages.

The bone marrow histology in cobalamin deficiency is similar to that in folic acid deficiency. Significant changes in the histology have been observed within 12 hours after appropriate treatment is initiated. The megaloblastic changes due to cobalamin deficiency can be reversed by pharmacologic doses of folic acid. However, folic acid therapy may worsen the neurologic consequences of cobalamin deficiency, despite the hematologic improvement.

### Other Tests

Gastric biopsy demonstrating total absence of hydrochloric acid in gastric secretions (achlorhydria) is diagnostic for pernicious anemia, as it is the only gastric lesion that leads to total achlorhydria. The achlorhyria in these cases is a direct result of the loss of gastric parietal cells.

## Pernicious Anemia Treatment & Management

### Approach Considerations

The following goals are the most important in establishing care for patients with pernicious anemia:

- To establish that the patient has cobalamin deficiency
- If there is evidence for folic acid deficiency but pernicious anemia has not been ruled out, treat with both folic acid and cobalamin until pernicious anemia has been ruled out. The reason is that folic acid restores blood counts but does not prevent the development of subacute combined system degeneration in patients with pernicious anemia.
- To determine the cause of the failure to absorb cobalamin (This goal is somewhat controversial. Not all hematologists work to establish the precise cause of low vitamin B12 levels. The nuclear medicine tests are expensive and cumbersome, and as a result, many hematologists simply proceed to treatment once a differential diagnosis of a low vitamin B12 state is established.)
- To treat the patient with adequate doses of cobalamin
- To confirm the diagnosis by documenting that specific therapy is effective
- To ensure administration of adequate quantities of cobalamin for the lifespan of the patient

Once therapy is started, hospitalization is necessary only for patients with severe life-threatening anemia. It may be required until patients develop an adequate hematologic response. Patients whose cobalamin deficiency is due to underlying diseases involving the intestine or pancreas may require additional therapy. Examples of additional therapy are surgical correction of anatomic abnormalities of the gut that produce small bowel bacterial overgrowth, or the treatment of fish tapeworm anemia or pancreatitis. Elderly patients who also have hypokalemia should receive oral potassium supplements, to prevent severe hypokalemia and possible arrhythmias. Go to Anemia, Iron Deficiency Anemia, and Chronic Anemia for complete information on these topics.

# INTERPRETATION

## METHYL MALONIC ACID

### Reference Range

Methylmalonic acid (MMA) levels are commonly used to evaluate for vitamin B-12 deficiency. The normal value for MMA is < 3.6 µmol/mmol creatinine.

### Interpretation

Methylmalonic acid (MMA) levels are increased in association with the following:

- Vitamin B-12 deficiency
- Methylmalonic acidemia in children
- Cobalamin genetic defects and pregnancy
- Pernicious anemia
- Renal insufficiency
- Elderly (5%-15%)

### Collection and Panels

Specimen: Blood
Container: Tiger-, lavender-, or green-top tube
All samples must be sent in a sealed, leak-proof container marked with a biohazard sticker to comply with Occupational Safety and Health Administration safety standards.

### Background

#### Description

Cobalamin plays a vital role in DNA synthesis and neuropsychological function. Its deficiency may lead to a wide spectrum of hematologic and neuropsychiatric disorders that can often be reversed by early diagnosis and prompt therapy. According to the Framingham Offspring Study, vitamin B-12 deficiency may be more common than was previously believed. Vitamin B-12 deficiency is thought to be related to improper absorption rather than a decreased amount of dietary vitamin B-12, as many persons who consume large amounts of the vitamin still have a deficiency. Methylmalonic acid (MMA) is an intermediate in the propionate pathway. Deficiency of methylmalonyl CoA mutase, an enzyme responsible for conversion of methylmalonic CoA to succinyl CoA, results in methylmalonic aciduria, which has a poor outcome if it remains untreated. The classic presentation includes neonatal metabolic acidosis and an increased serum ammonia level. Vitamin B-12 deficiency results in megaloblastic anemia, pancytopenia, peripheral neuropathy, dementia, depression, psychosis, subacute combined degeneration of cord, and, possibly, a heightened risk for vascular diseases such as myocardial infarction and strokes. The reference range of vitamin B-12 is typically wide. The lower end of the normal level is associated with clinical diseases due to vitamin B-12 deficiency. Therefore, upon clinical suspicion of vitamin B-12 deficiency in the setting of low normal laboratory values, MMA and homocysteine testing should be performed, since these tests are considered to be more sensitive metabolic markers of vitamin B-12 status. Both of these markers are elevated in vitamin B-12 deficiency. As homocysteine may be affected by other factors, such as renal failure, folate deficiency, tobacco, and alcohol abuse, it is less specific than MMA for identifying vitamin B-12 deficiency.

#### Indications/Applications

MMA testing is indicated for the following:

- Evaluation of methylmalonic academia in children
- Evaluation of megaloblastic anemia, as serum MMA is more sensitive than vitamin B-12 in vitamin B-12–deficiency states

#### Considerations

Although MMA is a more sensitive and specific marker of vitamin B-12 status, its assay is expensive and requires specialized instrumentation and is therefore unavailable in most clinical laboratories. Age and nutritional status should be considered in the assessment of serum MMA. It is unclear why increased serum MMA levels are more common (5%-15%) in elderly persons with low or normal serum vitamin B-12 levels. Pernicious anemia has been confirmed in only a few of such persons. Vitamin B-12 deficiency can be excluded by a normal MMA level in persons with lymphoid disorders who have low unexplained vitamin B-12. In persons with HIV infection, who typically have low levels of vitamin B-12–binding proteins, the vitamin B-12 level may be low, but, again, the MMA level is normal in this scenario. When the MMA level is mildly increased (0.4-2 µmol/L), vitamin B-12 supplementation has no significant effect on hemoglobin; mean corpuscular volume (MCV); or anemic (hematological), neurological, or gastroenterological symptoms, at least in the short term, despite normalization of the MMA level. The urine MMA level (reference interval: 0-3.6 mmol/mol creatinine) is helpful not only in monitoring patients with methylmalonic aciduria but also in evaluating vitamin B-12 status. Because most patients with folate deficiency have normal MMA levels, and the remainder have only mild elevations, vitamin B-12 deficiency can be differentiated from folate deficiency with the combined use of homocysteine and MMA levels. When the patient receives replacement with the deficient vitamin, the abnormal metabolites normalize. A positive response to vitamin B-12 replacement, evidenced by decreasing levels of homocysteine and MMA, is proof of vitamin B-12 deficiency. Conversely, folate treatment in a patient with folate deficiency results in a fall in the isolated homocysteine level. As several non–vitamin deficiency–related variables (eg, age, mild renal dysfunction) can falsely raise serum homocysteine and MMA levels, evidence of vitamin deficiency requires clear-cut demonstration of a decrease in metabolite levels after treatment with a specific vitamin.

# TROUBLESHOOTING

## VITAMIN B12 ESTIMATION

### What is the purpose of a vitamin B12 level test?

A vitamin B12 level test checks the amount of vitamin B12 in the body. Normal levels usually range from 200 to 900 picograms per milliliter, but the way of measuring will depend on the laboratory.

Vitamin B12 is necessary for several bodily processes, including nerve function and the production of DNA and red blood cells.

A person whose vitamin B12 levels are outside of the normal range will require treatment. High B12 levels may indicate liver disease, diabetes, or certain types of leukemia. Low levels of the vitamin may indicate a B12 deficiency or pernicious anemia.

### Why is a vitamin B12 level test useful?

The vitamin B12 level test checks how much vitamin B12 is in the body. The results can help doctors to determine if abnormal vitamin B12 levels are causing symptoms.

A doctor may order a vitamin B12 level test if a person has any of the following:

#### Suspected vitamin B12 deficiency

According to researchers, in the USA, approximately 6% of adults younger than 60 have vitamin B12 deficiency. That rate jumps to 20% in people ages 60 and over. Signs and symptoms of deficiency include:

confusion

- dementia
- depression
- difficulty maintaining balance
- fast heartbeat
- numbness and tingling in the hands and feet
- poor memory
- a sore mouth or tongue

Infants with vitamin B12 deficiency may fail to thrive. They may experience movement problems in addition to delayed development. If left untreated, it can lead to brain damage.

#### Pernicious anemia

People with symptoms of pernicious anemia may also need a vitamin B12 level test. Pernicious anemia, which causes low levels of red blood cells, results from an inability to absorb vitamin B12.

It often affects older adults or those who lack intrinsic factor. Intrinsic factor is a substance in the stomach that binds to vitamin B12 so that the body can absorb it.

#### Symptoms of pernicious anemia

- indigestion
- fatigue
- loss of appetite
- pale skin
- weakness
- weight loss.

#### High serum folate levels

Serum folate is the level of folic acid in the blood. High serum folate levels can mask Trusted Source the symptoms of vitamin B12 deficiency and make its neurological symptoms worse.

They can also increase the likelihood of anemia.

#### Symptoms of other conditions

An abnormally high vitamin B12 status can be an early sign of:

- liver disease
- diabetes
- certain types of leukemia

A doctor may use the results of a vitamin B12 test to help form their diagnosis.

### How does the vitamin B12 level test work?

Doctors usually use a blood test to check vitamin B12 status, but home urine tests are also available. A doctor can check vitamin B12 as part of a standard blood test.

Although it is not necessary to fast before a B12 test, a person may need to if the doctor is also using the test to look at other components in the blood.

It is important that individuals tell their doctor about any medications and supplements they are taking, as some can affect the results.

#### Risk factors for low vitamin B12 levels

Certain people are more at risk of vitamin B12 deficiency than others, especially those who have low stomach acid or other digestive issues. Stomach acid separates vitamin B12 from food so that the body can absorb it more efficiently.

The following groups of people are more likely than others to experience low vitamin B12 levels:

- older adults
- vegans and vegetarians
- people with diabetes
- people with conditions that reduce vitamin B12 absorption, including celiac disease
- people who have had gastric bypass surgery
- people who are taking medicines such as chloramphenicol, proton pump inhibitors, or H2 blockers.

### Understanding the results

The results may be:

- **High.** An abnormally high vitamin B12 status is anything over 900 pg/mL. This result may suggest liver or kidney problems, diabetes, or certain forms of leukemia.
- **Low.** Levels of vitamin B12 are low if they are below 200 pg/mL. This result suggests a vitamin B12 deficiency, pernicious anemia, or an overactive thyroid. People with low vitamin B12 levels often experience neurological symptoms.

The result ranges vary from one laboratory to another, so it is important to discuss the results and their meaning with a doctor.

The doctor may also check the levels of methylmalonic acid (MMA) and other substances to evaluate for vitamin B12 deficiency. These lab values help detect a vitamin B12 deficiency during the early stages.

#### Treatment for high vitamin B12 levels

There is no upper limit for vitamin B12 intake because consuming high levels does not cause problems. However, having naturally high levels of vitamin B12 in the body may be a cause for concern, as it suggests a severe underlying condition. Doctors will aim to treat the underlying medical condition, rather than the elevated levels of vitamin B12.

### Treatment for low vitamin B12 levels

Individuals with low vitamin B12 levels often require regular injections of the vitamin. These shots are more effective than supplements at raising vitamin B12 levels, especially when people have medical conditions that may make it more difficult to absorb supplements.

For some people, high doses of vitamin B12 supplements may improve B12 status.

### Food sources of vitamin B12

Although absorption difficulties and other medical issues often cause low vitamin B12 levels, some people may be deficient because they do not get enough vitamin B12 from their diet. This is especially true for vegans and vegetarians.

Foods rich in vitamin B12 include:

- fish and seafood
- meat
- eggs
- dairy products
- fortified plant-based dairy alternatives
- fortified breakfast cereals
- fortified nutritional yeast

Vitamin supplements can make up for a shortfall in the diet, especially for vegans and strict vegetarians. As it can be easier for their body to absorb supplements than naturally occurring vitamin B12, older adults should aim to meet their vitamin B12 needs through fortified foods and vitamin supplements.

### Recommended dietary allowances of vitamin B12

Adults and adolescents over 14 years of age require 2.4 micrograms (mcg) of vitamin B12 daily. This increases to 2.6 mcg during pregnancy and 2.8 mcg when breast-feeding.

# BOUQUET

## In Lighter Vein

A little boy was in a bus eating a chocolate, then he took another one and then another ...
A man next to him said "Do you know that too much of it will damage your teeth"
The boy replied, "my grandfather lived for 132 years"
The man asked " was it because of eating chocolate?"
The boy replied, "No, he was always minding his own business!!!!

Teacher : Sani, if you had 5 dollars and you asked your mother for another 5, how many dollars would you have?
Sani : 5 dollars Sir!
Teacher : You don't know your Arithmetic.
Sani : But Sir, you don't know my mother!

## Crazy Jokes

Wife (angrily)- I don't believe this...
u forgot my birthday again??
How can you do this..

Husband- how can you expect me to remember your birthday when u never look older..
Wife(clear her throat and smile): jaanu Sacchi

Husband in his mind (sahi time pe dialogue aa gya beta...warna khatam tha tu aaj.. )

## Wisdom Whispers



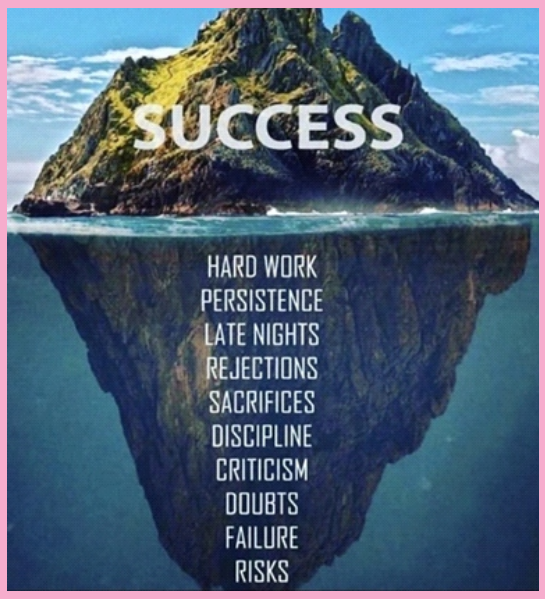


## Brain Teasers

1. **The enzyme ribonucleotide reductase requires the presence of-**
   A. Inositol C. B12
   B. B1 D. B2.

2. **Neurological manifestations are present in-**
   A. Dry beriberi C. B12 deficiency
   B. B6 deficiency D. All of the above.

3. **Schilling test is done to detect the deficiency of-**
   A. Riboflavin C. Niacin
   B. B12 D. Biotin.

4. **Sideroblastic anemia occurs due to the deficiency of vitamin-**
   A. B6 C. B3
   B. B12 D. B1.

ANSWER: 1: C, 2: D, 3: B, 4: A

# Towards the Future of Fluorescence Immunoassays

## Time Resolved Fluorescence Analyzer


## FIAcheck™ 1.0

- Time Resolved Fluorescence Immunoassay
- Faster TAT
- Convenient- One or two steps processes
- Secure Calibration

### FIAcheck™ Parameter Menu

| | | |
|---|---|---|
| Thyroid Markers | TSH | 25T |
| | TT3 | 25T |
| | TT4 | 25T |
| Fertility Marker | FSH | 25T |
| | LH | 25T |
| | PRL | 25T |
| | β-hCG | 25T |
| | AMH | 10T |
| Cancer Marker | PSA | 10T |
| Rhematology | Anti-CCP | 10T |

| | | |
|---|---|---|
| Diabetic Marker | HbA1C | 25T |
| Inflamation | CRP | 25T |
| | PCT | 10T |
| | IL-6 | 10T |
| Anemic Marker | Ferritin | 10T |
| Coagulation | D-Dimer | 10T |
| Cardiac Markers | cTnI | 10T |
| | NT-proBNP | 10T |
| Vitamins | Vitamin D | 10T |
| | Vitamin B12 | 10T |
| Allergy | IgE | 10T |

**Quality Products with Value Addition**

Printed and published by D.G. Tripathi, Edited by Dr. Ramnik Sood, M.D. (Path.) for and on behalf of Tulip Diagnostics Private Ltd., Gitanjali, Tulip Block, Dr. Antonio Do Rego Bagh, Alto Santacruz, Bambolim Complex Post Office, Goa - 403 202, INDIA.
E-mail: sales@tulipgroup.com Website: www.tulipgroup.com